



Official Journal of the  
Neuroscience Society of Nigeria  
(NSN)

**ORIGINAL ARTICLE**

<https://doi.org/10.47081/njn2016.7.2/004>  
ISSN 1116-4182

## Morphological and Histological Studies of Artesunate on the Developing Cerebral Cortex of Wistar Rat Foetuses

Emmanuel M. Samuel<sup>1</sup>, Andrew E. Ivang<sup>1</sup>, Augustine O. Ibegbu<sup>1</sup>

<sup>1</sup>Department of Human Anatomy, Faculty of Basic Medicine, Ahmadu Bello University, Zaria, Nigeria

Received: ..... November 2015

Accepted: ..... February 2016

### ABSTRACT

The longstanding use of artemisinin and its derivatives, mainly artesunate among pregnant women is recommended as first line treatment for malaria especially in endemic area like Nigeria. The present study investigated the morphological and histological effects of artesunate on the developing cerebral cortex of Wistar rat foetuses. Twenty healthy female Albino Wistar rats of average weight of 165 g were grouped into 4 with each group containing 5 rats. The rats were fed daily and water was allowed *ad libitum*. The animals were mated overnight with sexually matured males and were separated into different cages after confirmation of pregnancy. Oral doses of 0.2 mg/kg (low dose, LD), 0.4 mg/kg (medium dose, MD) and 0.8 mg/kg (high dose, HD) body weight of artesunate were administered to pregnant rats in LD, MD and HD groups respectively, from the 8th to the 12th day of gestation. Group 1 rats were the control, and received distilled water on the same days. The results showed a significant reduction in the morphometry of some body parts. The mean foetal body weights were 5.33 g, 5.14 g, 4.67 g and 3.78 g in the Control, LD, MD and HD groups respectively, while the mean crown-rump lengths were 3.67 cm, 3.43 cm, 3.00 cm and 3.00 cm in the Control, LD, MD and HD groups respectively. The histological examinations revealed some neurodegenerative changes in the developing cerebral cortex of Wistar rat foetuses. These neurodegenerative changes include reduction in thickness of the cortical zones, cell clustering and chromatolysis of the cells of cerebral cortex. The results showed that artesunate when administered in high dosages could be dangerous to the developing foetuses.

**Keywords:** *Artesunate, Wistar Rats Foetuses, Cerebral Cortex, Morphology, Histology*

### INTRODUCTION

Malaria is a mosquito-borne infectious disease in humans and other animals, usually transmitted by an infected female *Anopheles* mosquito bite (Nosten and White 2007; WHO 2014). *Falciparum* malaria is a mass killer that went out of control, developing resistance against the then active drug, chloroquine and sulfadoxine-pyrimethamine in Asia and South America which later spread to Africa and sub-regions (WHO 2010; Olumide and Raji 2011). Malaria is highly endemic in Nigeria and accounts for over 60% outpatient and 30% inpatient in Nigerian hospitals

and poses a major challenge to the country as it impedes human and economic development (Clark et al. 2004; Raji et al. 2005; WHO 2014).

Pregnant women are a high-risk group in malaria attack, being more susceptible and likely to develop

Correspondence: Dr. Augustine O. Ibegbu, Ph.D., Department of Human Anatomy, Faculty of Basic Medicine, Ahmadu Bello University, P.M.B. 81006, Zaria, Nigeria. Email: [aoibegbu@yahoo.com](mailto:aoibegbu@yahoo.com); +2348032188042

anaemia and are more likely to develop complications (Adisa et al. 2008). In sub-Saharan Africa, approximately 25 million pregnant women are at risk of *Plasmodium falciparum* infection every year, and one in every four women have evidence of placental infection at the time of delivery (Morakinyo et al. 2009; Clark 2012).

Artemisinin and its derivatives are a group of drugs that possess the most rapid action of all current drugs against *Plasmodium falciparum* malaria (Germain et al. 2010; Okafor 2013). Treatments containing an artemisinin derivative, artemisinin-based combination therapies (ACTs) are now the standard treatment worldwide for *P. falciparum* malaria (Nosten and White 2007). Studies have shown that the second most-common drug used by women during pregnancy as anti-malaria is artemisinin and its derivatives, after folic acid (Genovese et al. 2000; McGready et al. 2006) and it is used both on prescriptions and over-the-counter (White et al. 2006; Adisa et al. 2008).

The World Health Organization recommends intramuscular or intravenous artesunate as the first line treatment for severe malaria (WHO 2010; Lisewski et al. 2014). The rapidity of effect, availability of an intravenous and intramuscular formulation and convenient dosage regimen make artesunate an ideal choice for the treatment of severe malaria, including cerebral disease (Olumide and Raji 2011). Artesunate is a promising drug in the combat against malaria specifically the severe *P. falciparum* malaria (Nwanjo and Oze 2007). However, this should be the start of it all, because so much is yet to be done so as to make the promise of the drug a reality particularly in our society where these drugs are constantly abused (Nontprasert et al. 2002; Ngokere et al. 2004). The aim of the present study therefore was to investigate the effect of artesunate on developing cerebral cortex of albino Wistar rat foetuses.

## MATERIALS AND METHODS

### Experimental Setup/Design

Twenty (20) female Wistar rats of average weight of 160 g were bought from the Animal House of the Department of Human Anatomy, Ahmadu Bello University Zaria. The animals were kept in smaller animal holdings of the Department. They were divided into 4 groups (1, 2, 3 and 4), each contained 5 animals. The animals were fed with commercial rat feeds and clean tap water was provided *ad libitum*, and weight assessment was done throughout the experiment period using EC-500 digital weighing scale (Scientech Balance, U.S.A.). The experimental procedure was approved by the Ethics Committee of the Faculty of Veterinary Medicine, Ahmadu Bello University Zaria.

The animals were cycled and during the pro-oestrous phase of the oestrous cycle, they were caged overnight in groups of three per one sexually matured adult male rat in each group. Confirmation of pregnancy was done according to the method of Clark et al. (2004) in which the presence of sperm plug and in the vaginal smears obtained the following morning confirmed coitus and the sperm positive day was designated as day zero of pregnancy. Following the confirmation of pregnancy, the animals were separated into different cages and fed individually, so as to create a disturbance and stress-free environment.

### Drug Preparation and Administration

Artesunate (Bliss GVS Pharma Ltd; Batch No: ALE 45; NAFDAC Reg. No-04-9927) was purchased in Fameks Pharmacy, Samaru Zaria. Each tablet weighed 50 mg and was dissolved in 20 ml of distilled water. Low, medium and high dose groups, received the oral artesunate dosages of 0.2 mg/kg, 0.4 mg/kg and 0.8 mg/kg body weights respectively. The administration was for 5 days, from the 8th to the 12th day of gestation and was by oral gavages using the orogastric tube. Group 1 was the Control and received 2.0 ml/kg body weight of distilled water on the same days of administration.

On the 20th day of gestation, the pregnant rats were humanely sacrificed using ketamine anaesthesia. The foetuses were harvested by maternal abdominal incision and the average litter numbers, number of resorbed, dead, and malformed foetuses were recorded. Physical observations of the foetuses and the measurement of some anatomical parameters such as the crown-rump length (CRL), tail length (TL), fore-limb length (FLL) and hind-limb length (HLL) was done.

The retrieved foetuses were weighed and fixed in 10% formal saline. The heads were opened through sagittal incisions for easy removal of the cerebral cortex and then post-fixed. The tissues were then processed for histological examination and were stained with haematoxylin and eosin (H & E) routine stain.

### Statistical Analysis

Data obtained from morphological parameters were presented as mean  $\pm$  standard error of mean (SEM). Data were analyzed using Statistical Package for Social Sciences (SPSS) IBM version 20. One-way Analysis of Variance (ANOVA) was employed, followed by Turkey post hoc test, and values were considered significant at  $p < 0.05$ .

## RESULTS

### Morphologic Studies

The records of the Control, Low dose group, and Medium dose group, showed the same result, only the litter size of the pups in the different groups are seen to be varying, as those in the treatment groups look much more smaller when compared to those of the Control group. However, the high-dosed group recorded 6 malformations and 1 resorption as shown in Table 1 and Table 2.

### Morphometric Studies

The result of the morphometric studies showed that the foetuses of rats administered with 0.4 mg/kg and 0.6 mg/kg of artesunate showed significant reduction in all the parameters measured ( $P < 0.05$ ) when compared to Control and LD groups. The mean foetal weight in the HD group ( $3.78 \pm 0.22g$ ) was significantly reduced when compared to Control, LD and MD groups at  $p < 0.05$ . The results of crown-rump length (CRL) measurement, tail length (TL), forelimb length (FLL) and hind limb length (HLL) were significantly reduced in the MD and HD groups when compared to the Control and LD groups ( $p < 0.05$ ) as shown in Table 2.

### Histological Studies

The histological examination of the sections of the developing cerebral cortex reveal altered histo-architecture of the tissues in the artesunate-treated groups when compared to the control, while those of the higher treatment groups demonstrated greater extent of alteration when compared to those of lower group treatment groups.

Figure 1 showed the developing cerebral cortex of the Wistar rat foetuses with normal cellular architectural arrangement of the layers (A), with four layers namely; the Marginal zone, the Cortical zone, the Subcortical plate and the Intermediate zone with numerous normal pyramidal cells. While Figure 1 (B), showed the cerebral cortex of the LD group foetuses which revealed reduction in the layers of the cortex with some mild alterations in the cytoarchitecture of the cerebral tissues when compared to the Control tissues and higher treatment groups. The observed features include neuronal chromatolysis and the enlargement of cell bodies. Figure 1C showed the cerebral cortex of MD group foetuses, which revealed more

**Table 1: The morphologic records of the collected pups**

Group	ALN	NM	NR	ND	NL
Control	7	0	0	0	7
Low dose	7	0	0	0	7
Medium dose	7	0	0	0	7
High dose	7	6	1	7	0

ALN = Average litter number; NM = Number malformed; NR = Number resorbed; ND = Number dead; NL = Number living.

pronounced alteration and reduction in the layers of the cortex with some neurodegeneration when compared to the control and LD groups. The neurodegenerative changes observed include reduced thickness of the cortical layers, reduced number of cells, pyknosis showing cell body condensation and shrinkage, peri-vascular oedema and neuronal chromatolysis. Figure 1D showed the cerebral cortices of the HD group foetuses which revealed greater extent of alterations in the layers, including widespread chromatolysis, neuronal loss, pyknosis and vacuolations.

## DISCUSSION

The teratogenic potentials of artesunate has been shown to cause significant decrease in all the morphological parameters studied, including foetal birth weight, crown-rump length, tail length, forelimb length, hind limb length and the reducing body size with increasing dosage. The indices used in

**Table 2: Morphometric measurements**

Group	Treatment	N	F.Wt (g)	CRL (cm)	TL (cm)	FLL (cm)	HLL (cm)
1	2 ml/kg B.Wt D. water	7	5.33 $\pm 0.33$	3.67 $\pm 0.21$	2.00 $\pm 0.00$	1.67 $\pm 0.21$	2.00 $\pm 0.00$
2	0.2mg/kg B.Wt AS	7	5.14 $\pm 0.14$	3.43 $\pm 0.20$	1.57 $\pm 0.20$	1.57 $\pm 0.20$	1.71 $\pm 0.18$
3	0.4 mg/kg B.Wt AS	7	4.67 $\pm 0.33$	3.00 $\pm 0.00^*$	1.00 $\pm 0.00^*$	1.00 $\pm 0.00^*$	1.00 $\pm 0.00^*$
4	0.8 mg/kg B.Wt AS	7	3.78 $\pm 0.22^*$	3.00 $\pm 0.00^*$	1.33 $\pm 0.17^*$	1.00 $\pm 0.00^*$	1.00 $\pm 0.00^*$

Values are expressed as mean  $\pm$  SEM. \* = Significant at  $p < 0.05$ ; N = Average number of pups retrieved per group; B.Wt = Body weight of dams; AS = Artesunate; F.Wt = Foetal weight; D. water = Distilled water; CRL = Crown-rump length; TL = Tail length; FLL = Forelimb length; HLL = Hind limb length.

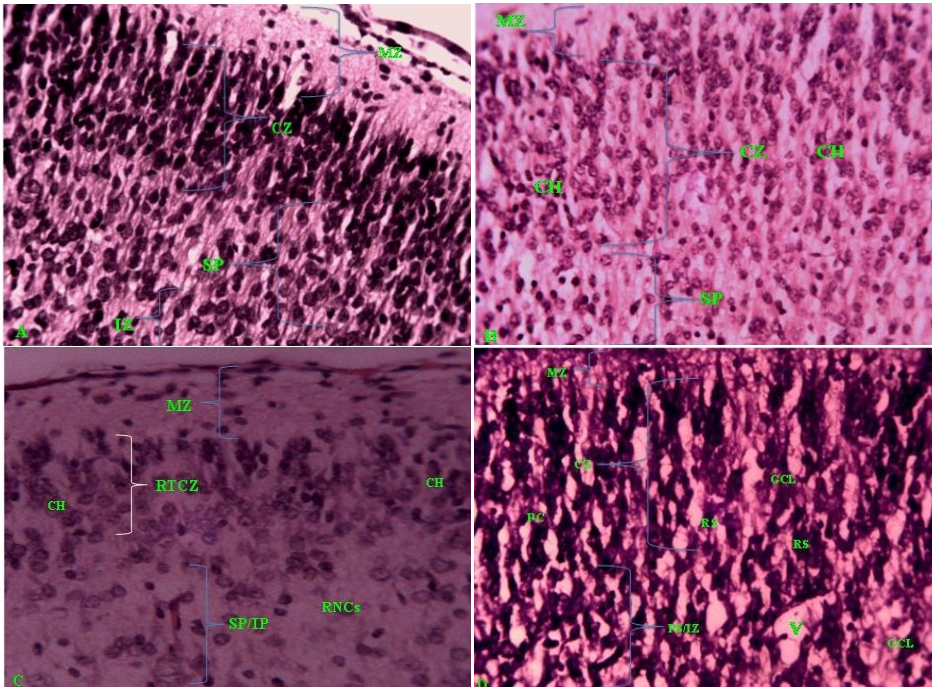


Fig. 1: Sections of the developing cerebral cortices of Wistar rat foetuses, showing normal histo-architecture of the developing cortical layers- Marginal zone (MZ); Cortical zone (CZ); Subcortical plate (SP) and Intermediate zone (IZ) as in Fig. A. While Fig. B show section of the developing cerebral cortex of Wistar rat foetuses from group treated with low dose of artesunate, showing disruption of the layers namely the Marginal zone (MZ); Cortical zone (CZ); Subcortical plate (SP) and Intermediate zone (IZ) and mild degenerative changes with chromatolysis (CH). Fig.C, show a section of the developing cerebral cortex of Wistar rat foetuses from group treated with medium dose, showing a more pronounced lost of layers namely Marginal zone (MZ); Cortical zone (CZ); Subcortical plate (SP) and Intermediate zone (IZ) with cellular loss and neuronal degeneration than in Groups 1 and 2. There was reduced thickness of cortical zone (RTCZ) and reduced number of pyramidal cells of intermediate zone (RNCs) and degenerative changes in individual cell (CH). Fig. D, show a Section of the developing cerebral cortex of Wistar rat foetuses from group treated with high dose. The cortical tissues showed widespread disruption in the layers Marginal zone (MZ); Cortical zone (CZ); Subcortical plate (SP) and Intermediate zone (IZ) with chromatolysis (WCH); Greater cells loss (GCL); Vacuolation (V) and Pyknotic cell (PC). H & E x250.

assessing growth included body weight, crown-rump length and tail length (Raji et al. 2005; Izunya et al. 2010; Okafor 2013). Thus, the present study revealed some parameters of reduced foetal growth (intrauterine growth retardation), following artesunate administration. This was in agreement with the studies and reports of Clark et al. (2004), Adebisi (2008) and Eluwa et al. (2008), who reported that the anti-malarial drug artesunate induced intrauterine growth retardation in developing foetuses.

The histological changes from the present study included neurodegeneration and distortion of the cells of the developing cerebral cortex of the Wistar rat foetuses. These changes included irregular pattern of cells in the cortical and intermediate zones of developing cerebral cortex, reduced population of pyramidal cells in the subcortical plate and intermediate zone, reduced thickness of the cortical zone, cell clustering, chromatolysis, pyknosis and vacuolations of the cells of the developing cerebral cortex of which the effects were increased with

increasing dosage. Specific studies reporting the effects of this drug on the developing foetuses, have revealed the teratogenic effects of the drug on other parts of the brain, thus revealing the vulnerability and susceptibility of the developing brain to some agents administered during the critical period of pregnancy (neurulation) (Izunya et al. 2010; Clark, 2012). The observed effects could imply compromised functions of the cerebral cortex, leading to many other complications. For example, the distortion of the cells of the cortex could induce reduced cortical activities hence other related complications. The degenerated cells of the developing cerebral cortex could impair the sensory and motor functions of the body, like ability to feel, speak and learn depending on the region of the cerebral cortex affected (Ekong et al. 2008; Eluwa et al. 2008; Eweka and Adjene 2008). The present study could be seen in the light of the work of Ajibade et al. (2012) who reported that artesunate when administered to adult

Wistar rat causes neuronal degeneration and reduced population of Purkinje cells in cerebellar cortex. Ajibade et al. (2012) also reported reduced staining of neuronal cells following artesunate administration. Eweka and Adjene (2008) had reported that medial geniculate body showed some decreased cellular population, degenerative changes, cellular hypertrophy, with some vacuolations appearing in the stroma. Eluwa et al. (2008) reported marked distortion and disappearance of the intermediate zone of the developing cerebral cortex, a merging of the subventricular and intermediate zone and reduction in the cortical and subventricular zones in the treated groups suggesting that fermented palm wine and beer is teratogenic to the developing cerebral cortex of Wistar rats. The present study strongly reaffirmed the findings of Clark et al. (2004) on the effects of artesunate in high dosages on the developing cerebral cortex of Wistar rat foetuses.

## CONCLUSION

The result of the present study revealed that artesunate had some toxic and teratogenic effects, involving growth retardation and neurodegeneration of the cerebral cortex in developing Wistar rat fetuses. These alterations with high dosage of the drug could become evident in later life and later developmental processes of the pups. Hence, care needs be taken when administering the drug during pregnancy, paying attention to the dosage in particular, especially during the brain-sensitive period of development from 3rd to 8th weeks of gestation or first trimester.

## REFERENCES

- Adebisi S. S. (2008) The toxicity of artesunate on bone developments: the Wistar rat animal model of malaria treatment. *The Internet Journal of Parasitic Diseases*. 4(1).
- Adisa, T. O., Fakeye, T. O. and Dike, D. (2008) Evaluation of adverse drug reactions of artemisinin based combination therapy in a Nigeria university community. *Tropical Journal of Pharmaceutical Research*. 7(2): 937-944.
- Ajibade, A. J., Fakunle, P. B. and Shallie, P. D. (2012) Some histological observations and microstructural changes in the Nissl substances in the cerebellar cortex of adult Wistar rats following artesunate administration. *Current Research in Neuroscience*. 2: 1-10.
- Clark, R. L., White, T. E. K., Clode, S. A., Gaunt, I., Winstanley, P. and Ward, S. A. (2004) Developmental toxicity of artesunate and an artesunate combination in the rat and rabbit. *Birth Defects Research Part B: Developmental and Reproductive Toxicology*. 71: 380-394.
- Clark, R. L. (2012) Effects of artemisinins on reticulocyte count and relationship to possible embryotoxicity in confirmed and unconfirmed malarial patients. *Birth Defects Research. Part A, Clinical and Molecular Teratology*. 94(2): 61-75.
- Ekong, M. B., Igiri, A. O. and Egwu, A. O. (2008) Histomorphological alteration of the cerebellum of Wistar rats following amodiaquine administration. *Internet Journal of Medical Update*. 2(4): 15-18.
- Eluwa, M., Njoku, C., Ekanem, T. and Akpantah, A. (2008) Teraogenic effect of beer and palm wine on histology of fetal cerebral cortex of Wistar rats. *The Internet Journal of Health*. 9(1).
- Eweka, A. O. and Adjene, J. O. (2008) Histological studies of the effects of oral administration of artesunate on the medial geniculate body of adult Wistar rats. *Electronic Journal of Biomedicine*. 1: 20-26.
- Genovese, R. F., Newman, D. B. and Brewer, T. G. (2000). Behavioral and neural toxicity of the artemisinin antimalarial, arteether, but not artesunate and artelinate, in rats. *Pharmacology Biochemistry and Behavior*. 67(1): 37-44.
- Germain, N., Banda, E. and Grabel, L. (2010) Embryonic stem cell neurogenesis and neural specification. *Journal of Cellular Biochemistry*, 111(3): 535-542.
- Izunya, A. M., Nwapora, A. O., Aigbiremolen, A. and Oaikhena, G. A. (2010) Body and testicular weight changes in adult Wistar rats following oral administration of artesunate. *Research Journal of Applied Sciences and Engineering and Technology*. 2(3): 302-306.
- Lisewski, A. M., Quiros, J. P., Ng, C. L., Adikesavan, A. K., Miura, K., Putluri, N., Eastman, R. T., Scandfeld, D., Regenbogen, S. J., Altenhofen, L., Llinás, M., Sreekumar, A., Long, C., Fidock, D. A. and Lichtarge, O. (2014) Super genomic network compression and the discovery of exp1 as a glutathione transferase inhibited by artesunate. *Cell*. 158(4): 916-928.
- McGready, R., Stepniewska, K., Ward, S. A., Cho, T., Gilveray, G., Looareesuwan, S., White, N. J. and Nosten, F. (2006) Pharmacokinetics of dihydroartemisinin following oral artesunate treatment of pregnant women with acute uncomplicated falciparum malaria. *European Journal of Clinical Pharmacology*. 62: 367-371.
- Morakinyo, A. O., Oludare, G. O., Ojulari, S. and Afolabi, A. O. (2009) Effects of short term administration of artemether-lumefantrine on testicular functions and antioxidant defence in the rat. *Research Journal of Medicine and Medical Science*. 4(2): 165-170.
- Ngokere, A. A., Ngokere, T. C. and Ikwdinma, A. P. (2004) Acute study of histomorphological and biochemical changes caused by artesunate in visceral organs of rabbit. *Journal Experimental and Clinical Anatomy*. 3(2): 11-16.
- Nontprasert, A., Pukittayakamme, S., Dandorp, A. M., Clemens, R. and White, N. J. (2002) Neuropathologic toxicity of artemisinin derivatives in mouse model. *American Journal of Tropical Medicine and Hygiene*. 67: 423-429.
- Nosten, F. and White, N. J. (2007) Artemisinin-based combination treatment of falciparum malaria. *American Journal of Tropical Medicine and Hygiene*. 77(6): 181-192.
- Nwanjo, H. U. and Oze, G. (2007) Hepatotoxicity following administration of artesunate in male guinea pig. *The Internet Journal of Toxicology*. 1(4): 781.
- Okafor, U. E. (2013) The effect of chronic administration of artemisinin-based combination therapies on the blood, liver and reproductive organ of Plasmodium berghei infected albino rats (*Rattus rattus*). M.Sc Thesis, Nnamdi Azikiwe University, Enugu-Nigeria.
- Olumide, S. A. and Raji, Y. (2011) Long-term administration of artesunate induces reproductive toxicity in male rats. *Journal of Reproductive and Infertility*. 12(4): 49-65.

Raji, Y., Osonuga, T. O., Akinsomisoye, O. S., Osonuga, O. A. and Mewoyeka, O. O. (2005) Gondotoxicity evaluation of oral artemisinin derivatives in male rats. *Journal of Medical Science*. 5: 303-306.

White, T. E. K., Bushdid, P. B., Ritter, S., Laffan, S. B. and Clark, R. L. (2006) Artesunate-induced depletion of embryonic erythroblasts precedes embryoletality and teratogenicity in vivo. *Birth Defects Research Part B: Developmental and Reproductive Toxicology*. 77: 413-429.

World Health Organization (2010) Guidelines for the treatment of malaria (2nd ed.). Geneva. Available from: [http://www.who.int/mediacentre/news/releases/2010/malaria\\_20100308/en/](http://www.who.int/mediacentre/news/releases/2010/malaria_20100308/en/). [Accessed: 14th January, 2014].

World Health Organization (2013) Guidelines for the treatment of malaria; Second edition. World Health Organization. Available from: <http://apps.who.int/medicinedocs/en/d/Js19105en/>. [Accessed: 10th January, 2014].